

Technical Note Orthognathic Surgery

Virtual model surgery and wafer fabrication for orthognathic surgery

J.-Y. Choi¹, K.-G. Song²,
S.-H. Baek²

¹Department of Oral and Maxillofacial Surgery, School of Dentistry, Dental Research Institute, Seoul National University, Seoul, South Korea; ²Department of Orthodontics, School of Dentistry, Seoul National University, Seoul, South Korea

J.-Y. Choi, K.-G. Song, S.-H. Baek: Virtual model surgery and wafer fabrication for orthognathic surgery. *Int. J. Oral Maxillofac. Surg.* 2009; 38: 1306–1310. © 2009 International Association of Oral and Maxillofacial Surgeons. Published by Elsevier Ltd. All rights reserved.

Abstract. Model surgery is one of the most important steps in the preoperative workup for orthognathic surgery. In cases of complicated two-jaw surgery, manual model surgery requires many laboratory based steps that are time-consuming and may contain potential errors. Recently, a three-dimensional virtual model surgery (3D-VMS) program (3Txxer version 2, Orapix, Seoul, Korea) was introduced. The purpose of this article is to present a 3D-VMS case using combined data from 3D computed tomography and 3D virtual dental casts.

Keywords: 3D virtual model surgery; wafer fabrication.

Accepted for publication 15 June 2009

In the preoperative workup for orthognathic surgery, model surgery is one of the most important steps in determining treatment plans, decreasing the chance of surgical errors, achieving optimal outcomes, and fabricating surgical wafers.⁵ Traditionally, conventional manual model surgery (MMS) has been used for these purposes. The procedure for MMS is to: draw the reference lines on the casts; measure the distance between the teeth and the reference lines using calipers or an Erickson platform (Great Lakes Orthodontic Ltd., Tonawanda, NY, USA); section the segments of the casts; and move the segments according to the surgical treatment objective (STO).

In cases of complicated two-jaw surgery, the MMS requires many laboratory based steps that are time-consuming and may contain potential errors such as those in the placement of the reference lines and sectioning of the casts, errors in repositioning

the maxilla into the desired location in the three dimensional (3D) coordinates and errors in measuring the surgical movement of segments.¹

To reduce error from MMS, changes in the surgical sequence and use of special instruments have been introduced.^{3,5–7} These instruments are often complex and difficult to use and there are limitations on vector control.¹

A 3D virtual model surgery (3D-VMS) program (3Txxer version 1.0, Orapix, Seoul, Korea) was introduced.^{1,8} The steps in the 3D-VMS process are: scanning of dental casts and fabrication of 3D-virtual dental casts (accuracy: 20 µm); mounting the 3D virtual dental casts in a 3D virtual articulator; repositioning the 3D virtual dental casts according to the STO; fabricating a 3D virtual surgical wafer; materializing the 3D-virtual surgical wafer using a stereolithographic technique. This approach has some limitations. After face-bow transfer

and mounting of the dental casts, measurement of the 3D coordinates of each tooth's position is necessary to transfer the 3D coordinates for mounting the 3D virtual dental casts into the virtual articulator.

Recently, computer-assisted surgery using 3D craniofacial imaging and computer-aided design and manufacturing techniques has opened up new treatment possibilities in orthognathic surgery. Craniofacial images from 3D computed tomography (3D-CT) can be materialized into a rapid-prototype (RP) model that can be used for 3D cephalometric measurements and surgical simulation.^{2,4} A method that combines the RP model of the maxilla and the mandible with dental casts or resin duplicates has been proposed.^{9,10} This combined method is inaccurate owing to the relatively low resolution of CT data for reconstruction of the occlusal surface making it inappropriate for producing an accurate surgical wafer, until now.

Technology to replace the 3D-CT data of the dentition with 3D-virtual dental casts has been developed for a 3D-VMS program (3Txxer version 2.0, Orapix) to address the above issues. This article presents a 3D-VMS case using combined data from 3D-CT and 3D virtual dental casts.

Case report

An 18-year-old male complained of a prognathic mandible. Clinical evaluation, lateral cephalometric analysis and model analysis revealed a concave profile with mandibular protrusion and normodivergent pattern, reverse overjet (−4.0 mm), Class III molar relationship, upper and

lower arch length discrepancies (−2 mm and −5 mm, respectively) and lower dental midline deviation to the right side (Fig. 1). The patient had a history of fixed orthodontic treatment with non-extraction for 5 years.

The preoperative orthodontic treatment plan involved extraction of the third molars, dental decompensation and coordination of both arches. The STOs were maxillary advancement of 3 mm and posterior impaction of 2 mm with Le Fort I osteotomy and mandibular setback of 6.5 mm at the right side and 4.5 mm at the left side with bilateral sagittal ramus osteotomy.

The CT scans (Sensation 10, Siemens, München, Germany) were obtained 1

month prior to orthognathic surgery with 1.0 mm resolution. The CT data obtained were processed and reformatted in 3D views using V-Works 4.0 (CyberMed Inc., Seoul, Korea). After the preoperative data from 3D-CT and 3D virtual models with centric relation (CR) bite were obtained, 3D virtual skull and 3D virtual models were combined to reconstruct the occlusal surface accurately using the best fit method in 3D-VMS program (version 2.0, Orapix) using the stable structure such as the lingual surface of the upper teeth, canine and buccal eminences and hard palate of the maxilla, and occlusion data (Fig. 2A).

The Frankfort horizontal (FH) plane (a plane between the left orbitale, the right

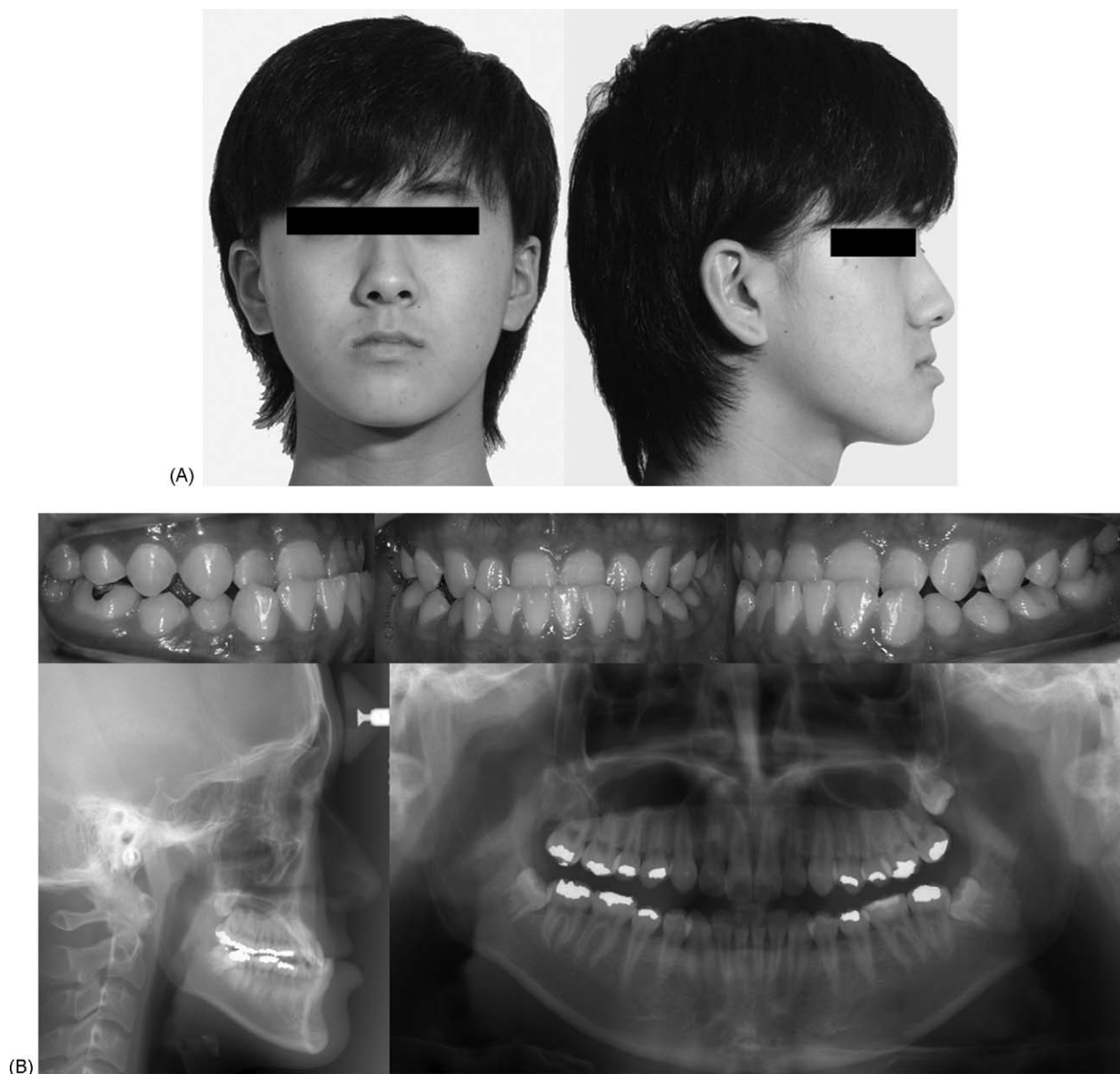


Fig. 1. An 18-year-old male patient with Class III malocclusion, prognathic mandible and facial asymmetry before treatment. (A) Facial photographs. (B) Intraoral photographs, lateral cephalometric radiograph and orthopantomograph.

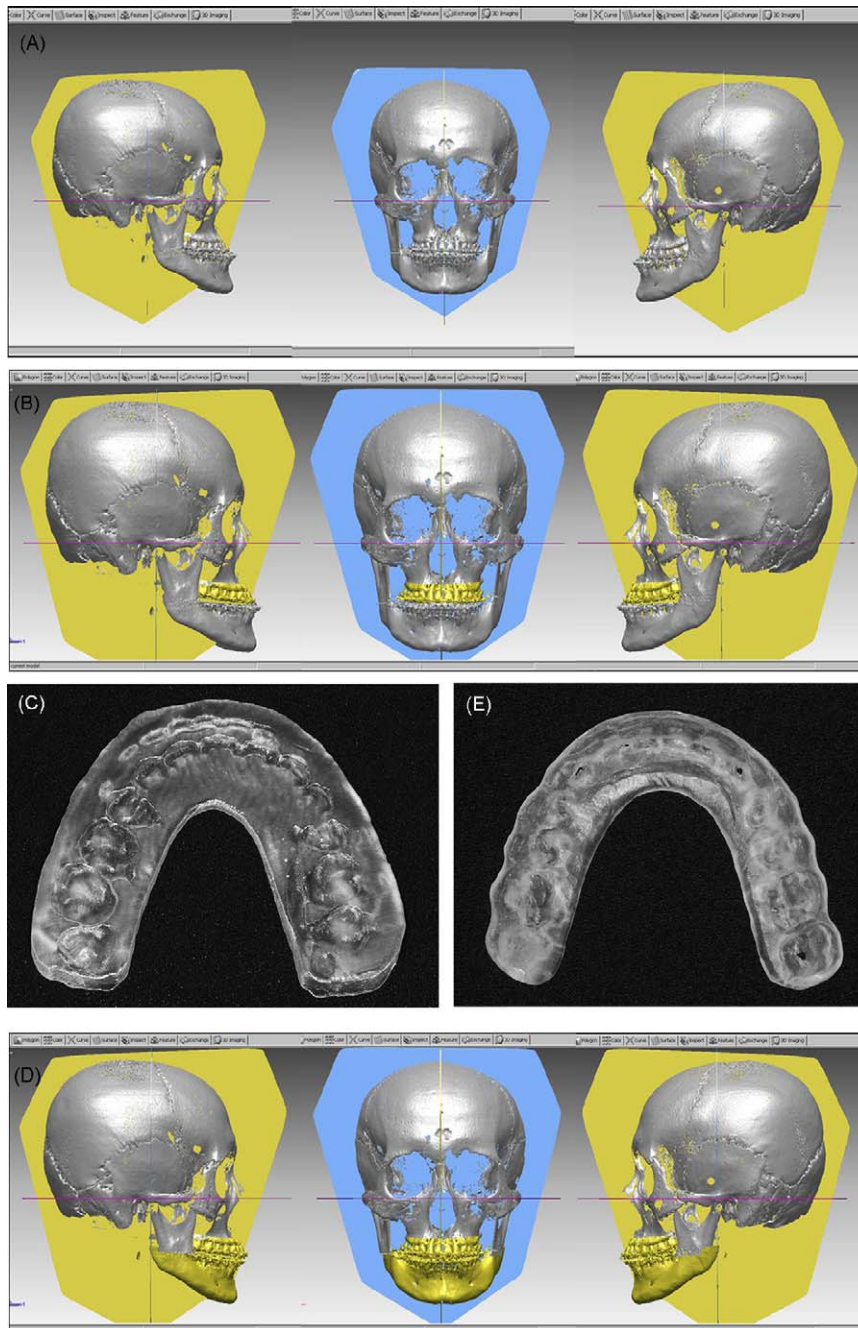


Fig. 2. 3D virtual model surgery procedure and wafer fabrication. (A) Preoperative 3D virtual skull model. (B) Repositioning of the maxilla according to the STO in a 3D virtual skull. (C) Materialization of the intermediate surgical wafer. (D) Setback of the mandible according to the STO in a 3D virtual skull. (E) Materialization of the final surgical wafer.

porion and the left porion), midsagittal plane (constructed with the most superior edge of the crista galli and the mid-point between the anterior clinoid processes and perpendicular to the FH plane), and frontal plane (constructed with the left and right ovale and perpendicular to the FH and midsagittal planes) of the 3D virtual skull were used as reference planes. The maxilla of the 3D virtual skull was repositioned according to the STOs (Fig. 2B).

The 3D virtual intermediate surgical wafer was fabricated by inserting a virtual object between the upper and lower dentition and making an indentation of the occlusal surfaces of the upper and lower teeth. After virtually cutting out the excess, the 3D virtual intermediate surgical wafer was materialized using a stereolithographic technique (Fig. 2C).

The mandible was set back along with the maxillary occlusal plane according to

the STO (Fig. 2D). Normal overbite and overjet and Class I canine and molar relationships were obtained after mandibular setback. The 3D virtual final surgical wafer was fabricated and materialized in the same way as the intermediate wafer fabrication using a stereolithographic technique (Fig. 2E).

After presurgical orthodontic treatment was completed, orthognathic surgery was performed. During surgery, the intermedi-

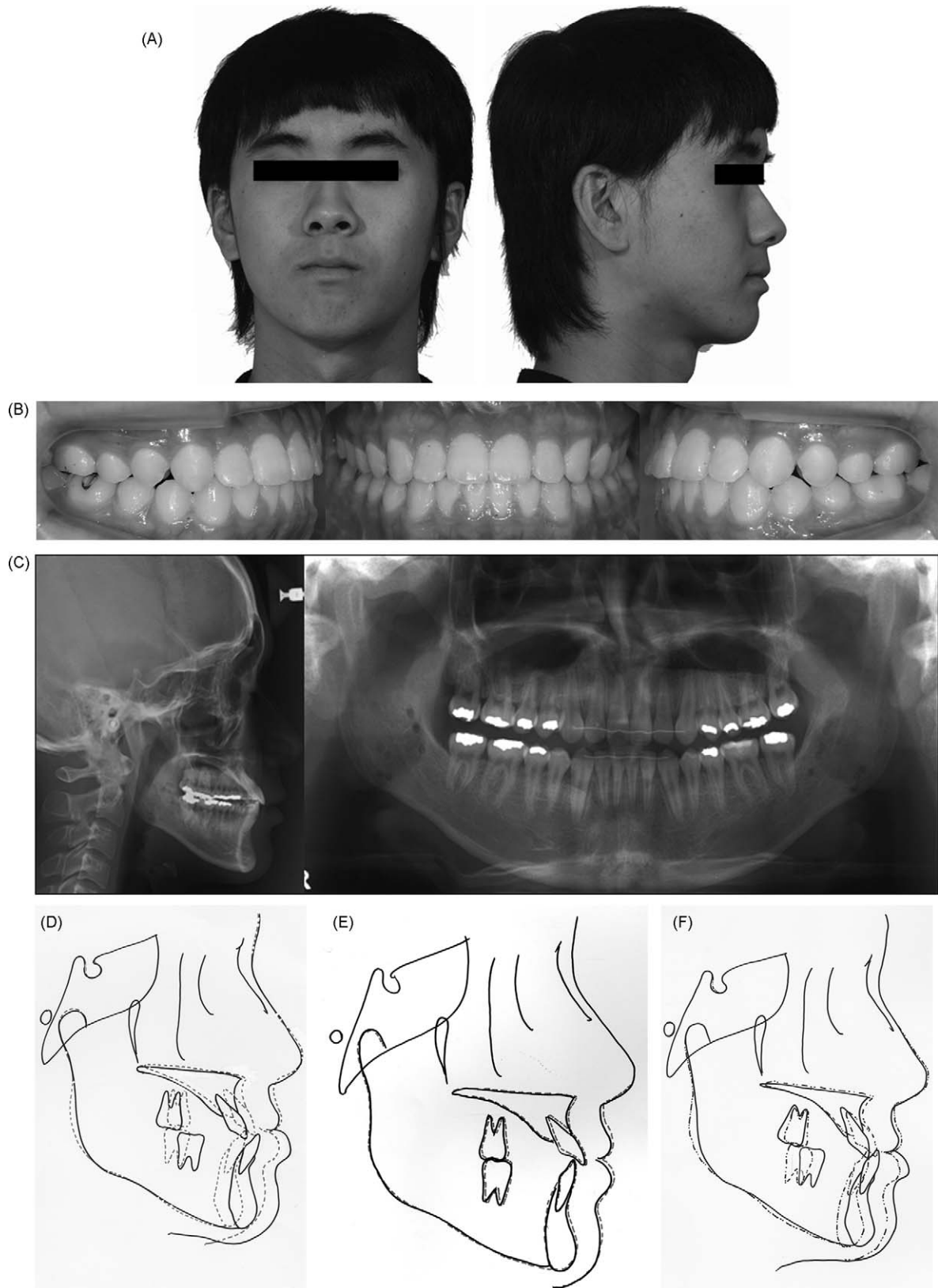


Fig. 3. After postoperative orthodontic treatment, a normal overbite and overjet were obtained, and the concave profile with mandibular prognathism and facial asymmetry was corrected. (A) Facial photographs. (B) Intraoral photographs. (C) Lateral cephalometric radiograph and orthopantomographs. Superimposition of (D) the preoperative (solid line) and postoperative (dotted line) lateral cephalometric tracings, (E) surgical treatment objectives (STOs, solid line) and post-treatment lateral cephalometric tracings (dotted line), and (F) the pre-treatment (solid line) and post-treatment (dashed and dotted line) lateral cephalometric tracings.

ate and final surgical wafers fitted well into the upper and lower dentition. The maxilla and mandible were repositioned according to the splints and fixed with Inion[®] biodegradable miniplates and screws (Inion Oy, Laakarinkatu 2, 33520 Tampere, Finland).

One month after orthognathic surgery, orthodontic treatment was resumed. Final arch coordination and occlusal settling were accomplished during the next 4 months. After debonding, the fixed and removable retainers were used. The total treatment period was 21 months. A normal overbite and overjet were obtained, and the concave profile with mandibular prognathism and facial asymmetry were both corrected (Fig. 3A–C).

When the pre- and postoperative lateral cephalometric tracings and STO and postoperative lateral cephalometric tracings were superimposed, the maxilla and mandible moved according to the STO (Fig. 3D–E). Superimposition of the pre- and post-treatment lateral cephalometric tracings shows that there was significant correction of the anteroposterior skeletal discrepancy and improvement of the soft tissue profile (Fig. 3F).

Discussion

Recently, the concept of 3D-VMS was introduced.^{1,8} SONG and BAEK⁸ compared the accuracy of model surgery between 3D-VMS and MMS. The errors with 3D-VMS (0.00–0.35 mm) were less than with MMS (0.00–0.94 mm), so they concluded that 3D-VMS was more accurate and clinically acceptable than MMS.⁸

In the present case, only 3D-CT data and preoperative dental casts with CR bite were needed for 3D-VMS. With the 3D-VMS program (3Txer version 2.0, Orapix), many laboratory based steps including face-bow transfer and mounting can be avoided, and the maxilla of a 3D virtual skull can be repositioned easily into an exact position based on 3D coordinates.

It takes less than 50 min for the whole process, including scanning of the upper and lower casts, fabrication of 3D virtual models, superimposition of the 3D virtual models and 3D-CT data, and 3D virtual

model surgery and six stereolithographic wafers can be fabricated simultaneously within 4 h using Viper Si2 (Viper SLA system, 3-D system Corporation, Valencia, CA, USA) and photo-activated resin (Accura SI 40 Nd type stereolithography resin, 3D Systems Inc, USA), therefore this method is less time-consuming and can reduce the amount of work that has to be performed in cases of MMS; it can also be used as a decision-supporting tool to evaluate several surgical options.¹ In conclusion, 3D-VMS is an effective alternative to MMS in complex and complicated surgery cases.

The patient was successfully treated with a combination of orthodontic treatment and orthognathic surgery with 3D-VMS, but this is a single case report. Further studies to ascertain the reliability of this method are needed.

Competing interests

None declared.

Funding

None.

Ethical approval

Not required.

References

1. BAEK SH, KANG SJ, BELL WH, CHU S, KIM HK. Fabrication a surgical wafer splint by three-dimensional virtual model surgery. In: BELL WH, GUERRERO CA, eds: *Distraction osteogenesis of the facial skeleton*. Hamilton: BC Decker Inc 2007: 115–130.
2. BETTEGA G, PAYAN Y, MOLLARD B, BOYER A, RAPHAËL B, LAVALLÉE S. A simulator for maxillofacial surgery integrating 3D cephalometry and orthodontia. *Comput Aided Surg* 2000; **5**: 156–165.
3. COTTRELL DA, WOLFORD LM. Altered orthognathic surgical sequencing and a modified approach to model surgery. *J Oral Maxillofac Surg* 1994; **52**: 1010–1020.
4. HASSFELD S, MUHLING J. Computer assisted oral and maxillofacial surgery:

a review and assessment of technology. *Int J Oral Maxillofac Surg* 2001; **30**: 2–13.

5. OMURA T, GLICKMAN RS, SUPER S. Method to verify the accuracy of model surgery and prediction tracing. *Int J Adult Orthodon Orthognath Surg* 1996; **11**: 265–270.
6. SCHWESTKA R, ENGELKE D, ZIMMER B, KUBEIN-MEESBURG D. Positioning control of the upper incisors in orthognathic surgery. Pre-operative planning with the Model Positioning Device and intra-operative application of the Sandwich Splint. *Eur J Orthod* 1991; **13**: 367–371.
7. SCHWESTKA-POLLY R, KUBEIN-MEESBURG D, LUHR HG. Techniques for achieving three-dimensional positioning of the maxilla applied in conjunction with the Gottingen concept. *Int J Adult Orthodon Orthognath Surg* 1998; **13**: 248–258.
8. SONG KG, BAEK SH. Comparison of accuracy of the model surgery and intermediate wafer fabrication between three-dimensional virtual method and conventional manual method. *Oral Surg Oral Med Oral Pathol Oral Radiol Endod* 2009; **107**: 13–21.
9. SWENNEN GR, BARTH EL, EULZER C, SCHUTYSER F. The use of a new 3D splint and double CT scan procedure to obtain an accurate anatomic virtual augmented model of the skull. *Int J Oral Maxillofac Surg* 2007; **36**: 146–152.
10. SWENNEN GR, MOMMAERTS MY, ABELLOOS J, DE CLERCQ C, LAMORAL P, NEYT N, CASSELMAN J, SCHUTYSER F. The use of a wax bite wafer and a double computed tomography scan procedure to obtain a three-dimensional augmented virtual skull model. *J Craniofac Surg* 2007; **18**: 533–539.

Address:

Seung-Hak Baek
 Department of Orthodontics
 School of Dentistry
 Dental Research Institute
 Seoul National University
 Yeonkun-dong #28
 Jongro-ku
 Seoul 110-768 South Korea
 Tel: +82 2 2072 3952
 Fax: +82 2 2072 3817
 E-mail: drwhite@unitel.co.kr

doi:10.1016/j.ijom.2009.06.009